

Case report

Open Access

Clinical significance of intraventricular gradient during effort in an adolescent karate player

Carlos Cotrim^{*1,3}, Ana G Almeida^{2,3} and Manuel Carrageta^{1,3}

Address: ¹Cardiology department, Garcia de Orta Hospital, Almada, Portugal, ²Cardiology department, Santa Maria Hospital, Lisboa, Portugal and ³Lisboa University Medical School, Lisboa, Portugal

Email: Carlos Cotrim* - carlosadcotrim@hotmail.com; Ana G Almeida - anagalmeida@hotmail.com; Manuel Carrageta - mcarrageta@mail.telepac.pt

* Corresponding author

Published: 19 November 2007

Received: 20 October 2007

Cardiovascular Ultrasound 2007, **5**:39 doi:10.1186/1476-7120-5-39

Accepted: 19 November 2007

This article is available from: <http://www.cardiovascularultrasound.com/content/5/1/39>

© 2007 Cotrim et al; licensee BioMed Central Ltd.

This is an Open Access article distributed under the terms of the Creative Commons Attribution License (<http://creativecommons.org/licenses/by/2.0>), which permits unrestricted use, distribution, and reproduction in any medium, provided the original work is properly cited.

Abstract

The authors report the case of a 16-year-old boy who practices karate, who underwent medical evaluation because of atypical chest discomfort, related to strenuous effort. The ECG and echocardiogram findings were normal. The young boy did a treadmill stress test which was positive for myocardial ischemia. Late during the investigation, he underwent treadmill stress echocardiography, during which he developed intraventricular gradient of over 130 mmHg with end-systolic peak and systolic anterior movement (SAM) of the mitral valve. These echocardiographic findings were not present at rest and disappeared shortly after termination of exercise. The authors discuss the significance of this event. This leads us to advise withdrawal from participation in competitive sport according to the recommendations of the European Society of Cardiology. A possible role of exercise stress echo for intraventricular pressure gradient assessment in symptomatic athletes with structurally normal hearts is suggested.

Background

The development of significant intraventricular gradients during exercise is rare, usually in association with left ventricular hypertrophy [1,2]. In 23-year-old athlete [3], in an 20-year-old professional soccer player [4], and in a 79 year-old man we performed exercise echocardiography [5], and during the exercise [6] we unexpectedly detected significant (greater than 50 mmHg) intraventricular gradient and systolic anterior movement of the mitral valve. In the case presented here, we describe an adolescent karate player that developed the same phenomenon.

Case report

We describe the case of a 16 year-old caucasian male, with a four-hour weekly training schedule, who complained of occasional chest discomfort on strenuous exercise. There

was no relevant personal history and no family history of sudden death or heart disease were reported.

Physical examination revealed normal cardiac auscultation and normal radial, carotid and femoral pulses. The twelve lead electrocardiogram was normal (Figure 1). The echocardiogram was also normal (Figure 2, see Additional file 1), with no left ventricular hypertrophy; left ventricular end-diastolic diameter was 41 mm, septum and posterior wall were 7 and 6 mm respectively, and the left ventricular outflow tract was 17 mm. No abnormalities were found in the mitral valve of subvalvular apparatus. Treadmill exercise test was performed following the Bruce protocol that was considered positive for to myocardial ischemia (Figure 3).

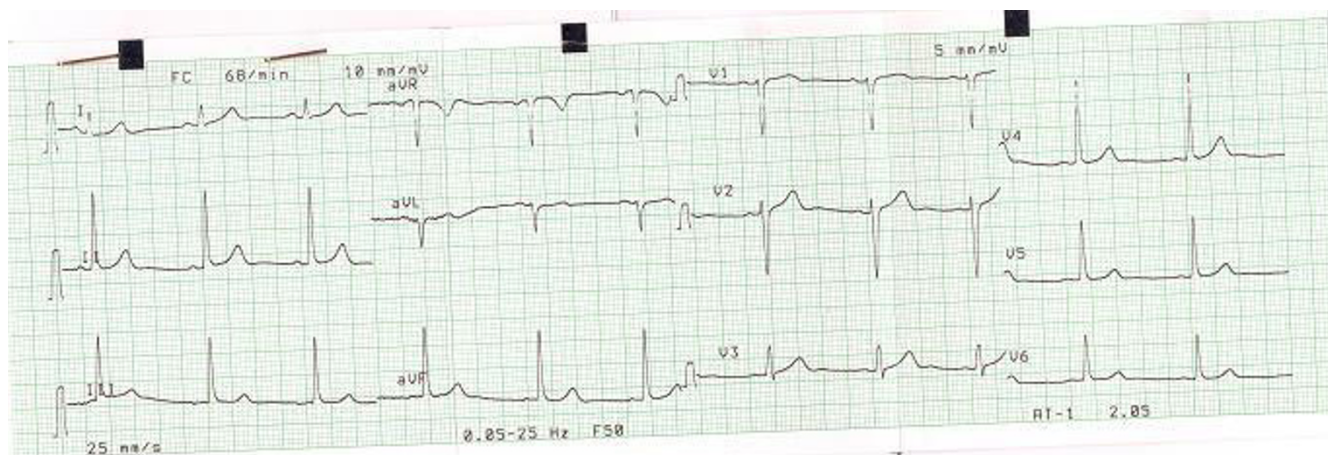


Figure 1
Normal ECG.

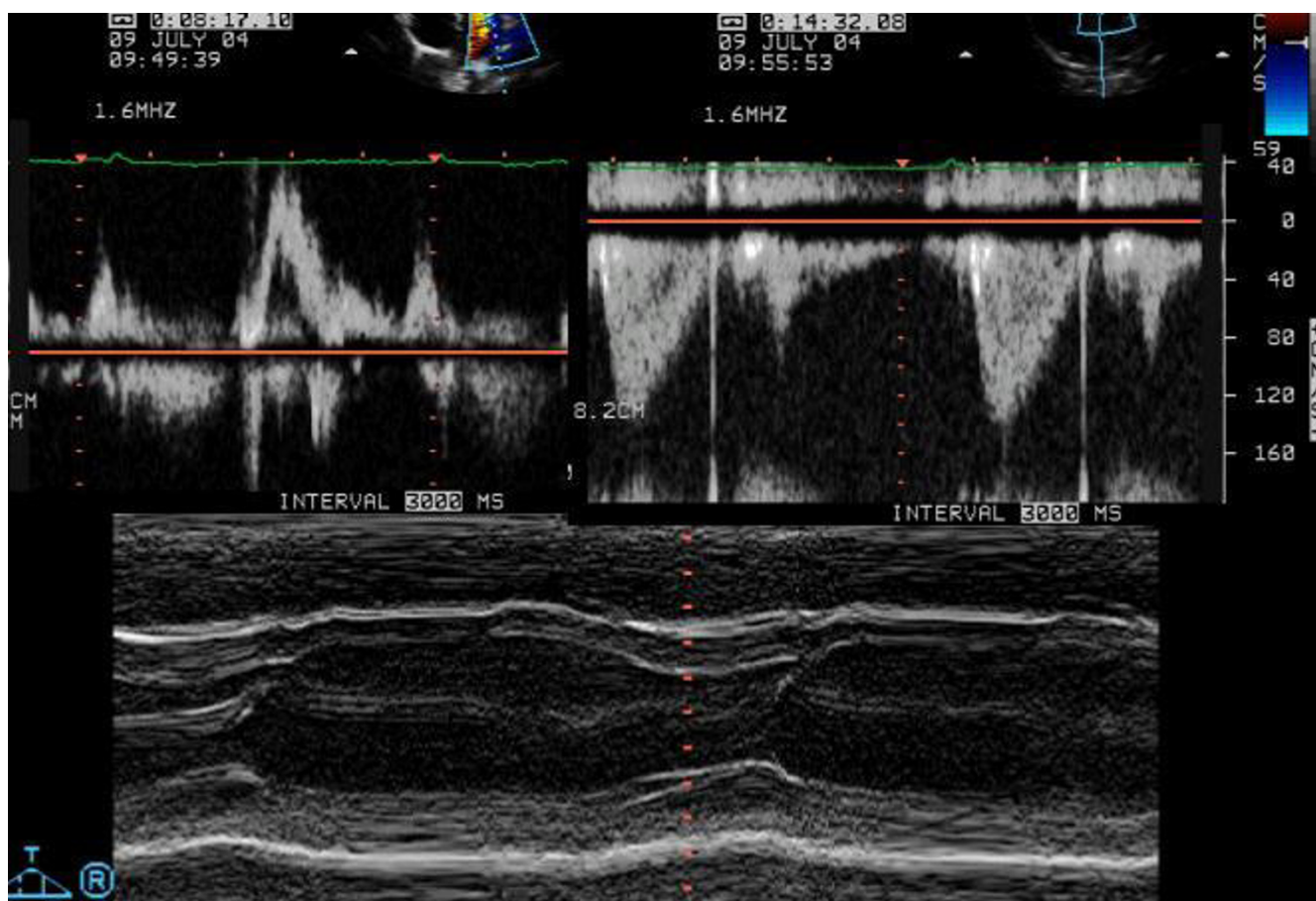


Figure 2
Normal echocardiogram without left ventricular hypertrophy.

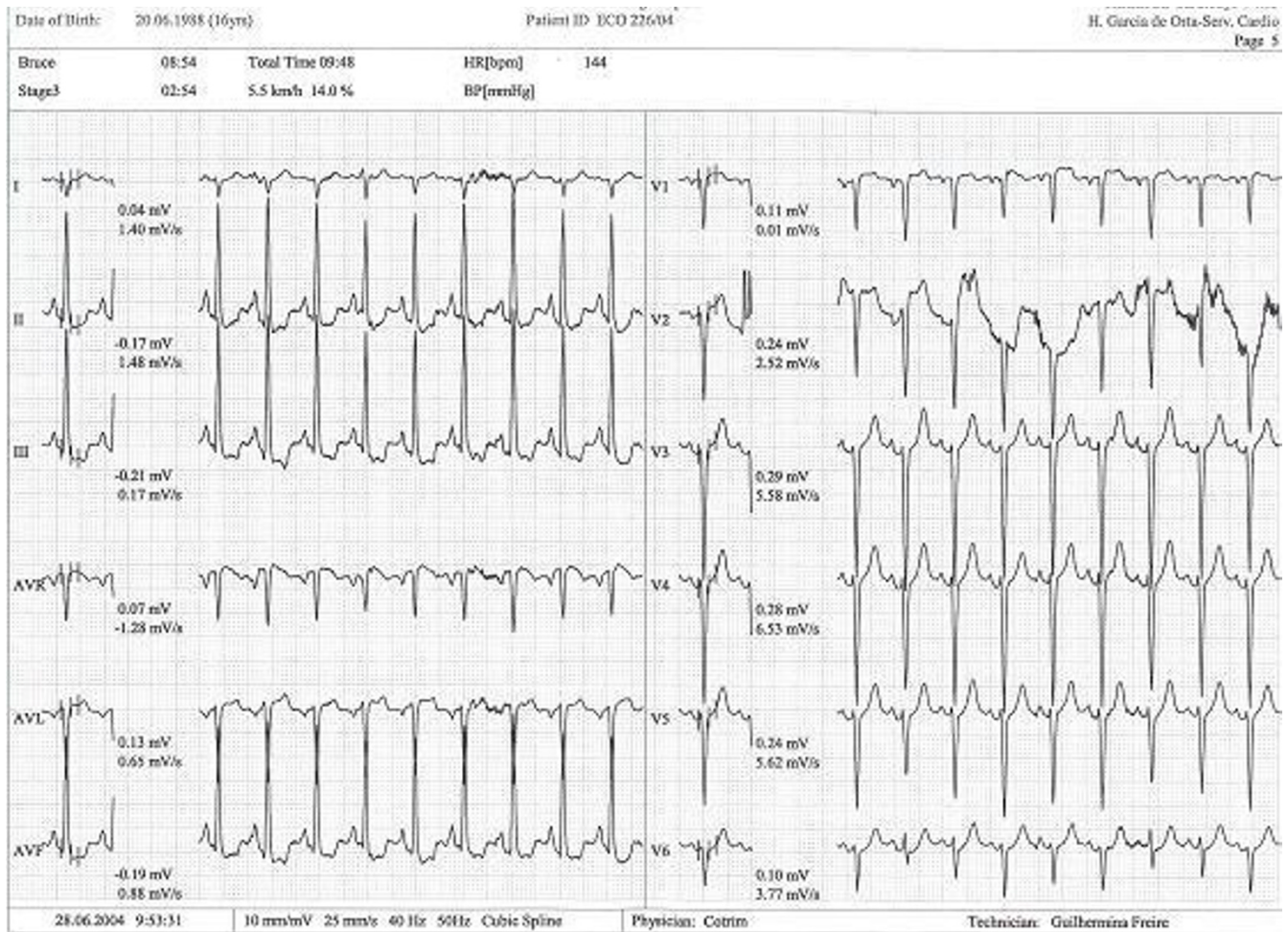


Figure 3
Exercise test with alteration in ST segment in DII, DIII and avF.

The patient underwent an exercise stress echocardiography, and during the exam developed a significant intraventricular gradient of 130 mmHg with an end-systolic peak and systolic anterior motion of the mitral valve (Figure 4, see Additional file 2), which disappeared in the first minute of recovery period. There was no fall in blood pressure at the end of the test. The exercise stress echocardiogram was negative for myocardial ischemia.

Discussion and conclusion

It has long been known that small intraventricular gradients are a common phenomenon. Three mechanisms have been proposed [7] for them increasing significantly during exercise: 1) increase in non-obstructive physiological gradients; 2) end-systolic obstruction secondary to ventricular cavity obliteration; and 3) mid-systolic obstruction caused by SAM of the mitral valve restricting ejection. However for SAM to occur, there must be some alteration of the geometry of the ventricular chamber or of

the mitral valve apparatus. This was not the case in our adolescent, although it has been demonstrated that intraventricular gradients can be caused by maneuvers that change loading conditions in structurally normal hearts [8], and it is known that participating in sports can bring about such changes.

Sudden death in young athletes has been thoroughly studied, and there is an agreement that the usual causes are hereditary or congenital [9]. However, in some series [10] around 30% of autopsy studies show no abnormalities, which suggests that the standard screening programs are failing to prevent sudden death.

In the case we report the fact that the patient had normal echocardiogram means that morphological study of this heart would probably reveal no abnormalities. The phenomenon that we detected during exercise testing – mitral valve SAM and intraventricular gradient associated with

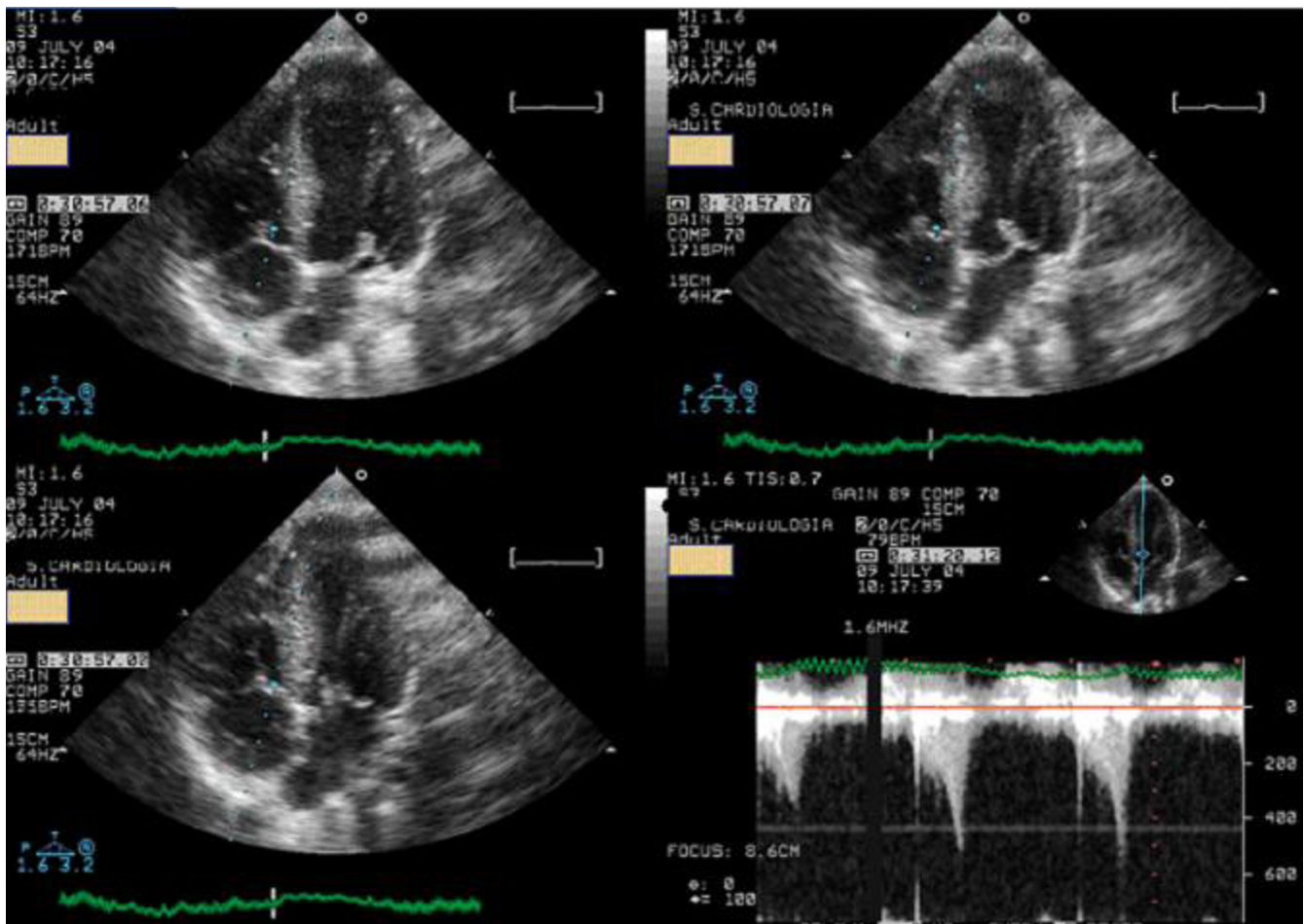


Figure 4
At peak exercise systolic anterior movement of mitral valve and significant intraventricular gradient was detected.

ST alterations – could well have been responsible for his symptoms.

The medical examination of this athlete was carried out because of symptoms arising from intense effort; we didn't reproduced the symptoms during exercise test but we detected an anomaly in cardiac function [2-5], that in our opinion may explain them. The abnormality detected is, however, only detectable during effort, and is not among the diagnosis that contraindicate participation in competitive sport according to recommendations of the 36th Bethesda conference [11] and the European Society of Cardiology [12]. It is possible tht the phenomenon described in this adolescent could be among the causes of sudden death in cases where anatomopathological examination reveals no abnormalities, and we accordingly advised the athlete to suspend sports practice and referred him for assessment to a sports medicine center. In our opinion, the case described, in which significant abnormalities in cardiac function were found only during exer-

cise, suggests that this methodology should be applied to other adolescents that have symptoms related to exercise but no structural abnormalities. We should note that this phenomenon has been almost excluded to be a normal response to exercise in young healthy adults [13]. In face of this, the symptomatic athletes in which the findings which we described is detected, should also be subjected of long term follow-up to obtain an accurate assessment of its clinical significance.

Additional material

Additional file 1

Apical 4 chamber view before exercise. Two-dimensional 4 chamber view, before exercise, showing normal morphology and funtion of left ventricle and mitral valve.

Click here for file

[<http://www.biomedcentral.com/content/supplementary/1476-7120-5-39-S1.avi>]

Additional file 2

Apical 4 chamber view at 13 minutes before end of exercise. Two-dimensional 4 chamber view, near peak exercise, showing clearly, systolic anterior movement of the mitral valve.

Click here for file

[<http://www.biomedcentral.com/content/supplementary/1476-7120-5-39-S2.avi>]

References

- Peteiro J, Monserrat L, Castro Beiras A: **Lábil subaortic obstruction during exercise stress echocardiography.** *Am J Cardiol* 1999, **84**:1119-23.
- Lau K, Navarajo J, Stainback F: **Pseudo-False-Positive Exercise Treadmill Testing.** *Tex Heart Inst J* 2001, **28**:308-11.
- Cotrim C, João I, Fazendas P, Cordeiro P, Sequeira A, Henriksson I, Oliveira L, Carrageta M: **Exercise induced ventricular gradient in a young patient with a positive treadmill test and normal coronary arteries.** *Rev Port Cardiol* 2002, **21**:331-5.
- Cotrim C, Loureiro M, Simões O, Cordeiro P, Henriksson I, Vinhas H, Almeida A, Carrageta M: **Intraventricular gradient during effort in a professional soccer player. Clinical significance.** *Rev Port Cardiol* 2005, **24**:1395-1401.
- Almeida S, Cotrim C, Brandão L, Miranda R, Loureiro M, Simões O, Lopes L, Carrageta M: **Exercise-Induced left ventricular outflow tract obstruction. A potential cause of symptoms in the elderly.** *Rev Port Cardiol* 2007, **26**:257-262.
- Cotrim C, Carrageta M: **Ecocardiografia de Sobrecarga – Esforço.** *Rev Port Cardiol* 2000, **19**:345-350.
- Yotti R: **Qué significado tiene un gradiente de presión intraventricular sistólico durante el ejercicio?** *Rev Esp Cardiol* 2004, **57**:1139-42.
- Grose R, Maskin C, Spindola-Franco H, Yipintsoi T: **Production of left ventricular cavity obliteration in normal man.** *Circulation* 1981, **64**:448-55.
- Firoozi S, Sharma S, McKenna W: **Risk of competitive sport in young athletes with heart disease.** *Heart* 2003, **89**:710-714.
- Paz M, Aguilera B: **Causes of Sudden Death During Sports Activities in Spain.** *Rev Esp Cardiol* 2002, **55**:347-58.
- Maron B, Zipes D: **36th Bethesda Conference. Introduction: Eligibility recommendations for competitive athletes with cardiovascular abnormalities – general considerations.** *J Am Coll Cardiol* 2005, **45**:1318-21.
- Corrado D, Pelliccia A, Bjørnstad H, Vanhees L, Biffi A, Borjesson M, Panhuyzen-Goedkoop N, Deligiannis A, Solberg E, Dugmore D, Mellwig KP, Assanelli D, Delise P, van-Buuren F, Anastasakis A, Heidebuchel H, Hoffmann E, Fagard R, Priori SG, Basso C, Arbustini E, Blomstrom-Lundqvist C, McKenna WJ, Thiene G, Study Group of Sport Cardiology of the Working Group of Cardiac Rehabilitation and Exercise Physiology and the Working Group of Myocardial and Pericardial Diseases of the European Society of Cardiology: **Cardiovascular pre-participation screening of young competitive athletes for prevention of sudden death: proposal for a common European protocol. Consensus statement of Study Group of Sport Cardiology of the Working Group of Cardiac Rehabilitation and Exercise Physiology and Working Group of Myocardial and Pericardial Diseases of European Society of Cardiology.** *Eur Heart J* 2005, **26**:516-524.
- Bueno F, Isabel R, Salguero R, Doblas J, Pinilla J, Galván E: **Effect of exercise on systolic left ventricular outflow velocity in healthy adults.** *Rev Esp Cardiol* 2006, **59**:180-2.

Publish with **BioMed Central** and every scientist can read your work free of charge

"BioMed Central will be the most significant development for disseminating the results of biomedical research in our lifetime."

Sir Paul Nurse, Cancer Research UK

Your research papers will be:

- available free of charge to the entire biomedical community
- peer reviewed and published immediately upon acceptance
- cited in PubMed and archived on PubMed Central
- yours — you keep the copyright

Submit your manuscript here:
http://www.biomedcentral.com/info/publishing_adv.asp

