

Case report

Open Access

Right atrium myxoma coexisting with antiphospholipid syndrome: a case report

Christos Pliakos¹, Eleni Alexiadou¹, Symeon Metallidis*¹,
Theodossis S Papavramidis², Stergios Kapoulas¹, Konstantinos Sapalidis² and
Pavlos Nikolaidis¹

Address: ¹1st Internal Medicine Department, Aristotle University of Thessaloniki, Thessaloniki, Greece and ²3rd Surgical Department, Aristotle University of Thessaloniki, Thessaloniki, Greece

Email: Christos Pliakos - pliakos@med.auth.gr; Eleni Alexiadou - alexiadou@yahoo.gr; Symeon Metallidis* - metallidissimeon@yahoo.gr; Theodossis S Papavramidis - papavramidis@hotmail.com; Stergios Kapoulas - kapoulas@med.auth.gr; Konstantinos Sapalidis - sapalidisk@yahoo.gr; Pavlos Nikolaidis - nikolp@med.auth.gr

* Corresponding author

Published: 11 October 2009

Received: 6 September 2009

Cardiovascular Ultrasound 2009, **7**:47 doi:10.1186/1476-7120-7-47

Accepted: 11 October 2009

This article is available from: <http://www.cardiovascularultrasound.com/content/7/1/47>

© 2009 Pliakos et al; licensee BioMed Central Ltd.

This is an Open Access article distributed under the terms of the Creative Commons Attribution License (<http://creativecommons.org/licenses/by/2.0>), which permits unrestricted use, distribution, and reproduction in any medium, provided the original work is properly cited.

Abstract

In this case report we describe a rare case of right atrium myxoma that coexisted with antiphospholipid syndrome in a young woman. We describe the unusual findings and diagnostic challenges combined with a review of the literature.

Background

Myxoma is the most common type of primary cardiac tumors and is usually localized in the left atrium. A right atrium myxoma is rarely observed. Its clinical presentation is ranging from an asymptomatic condition or constitutional symptoms to cardiac obstruction or pulmonary embolism. On the other hand, antiphospholipid syndrome is related to thrombotic conditions and the finding of a cardiac mass would be expected to be a thrombus. A comprehensive review of the literature reveals a limited number of cases with coexistence of cardiac myxoma and antiphospholipid syndrome.

Case report

A 28-year old female patient was admitted to our hospital because of two-day nausea and pain on the right upper quadrant of the abdomen. It was mentioned, in her medical history, an episode of acute but transient vision loss that lasted for a day, five years ago.

On admission, blood pressure was 130/85 mmHg, heart rate 84 beats/min, respiratory rate 16 breaths/min and temperature was normal. There were no clinical findings on cardiac auscultation. Except of mild pain on the right upper quadrant, the rest of the physical examination was unremarkable.

Laboratory tests revealed the following results: WBC = 11,6 K/ μ L, Hb = 13,7 g/dL, Ht = 39,9%, PTL = 95 K/ μ L, LDH = 384 U/l, AST = 16 U/l, ALT = 16 U/l, γ GT = 10 U/l, ALP = 58 U/l, bilirubin = 0,73 mg/dl, CRP = 0,07 mg/dl, ESR = 40 mm and urine test within normal limits. Chest X-ray didn't show any pathologic finding.

On further investigation, ultrasonography and computed tomography of the abdominal cavity were obtained and identified the presence of free fluid around the liver.

On the second day of the nursery, she had low-grade fever but her clinical condition worsened, with abdominal tenderness, hypotension and tachycardia. The patient was transferred to the surgical clinic and underwent investigational laparotomy. There were no special findings, appendectomy was performed and the histological examination of the appendix, a mesenteric lymph node revealed only signs of inflammation.

Two days after the surgery, the patient developed tachypnea, tachycardia and fever (temperature of 38,8°C). A computed tomographic scan of the chest and the abdomen was obtained as well as a transthoracic echocardiogram in order to rule out pulmonary embolism. The first imaging study showed infiltrations of the right lower lobe accompanied by pleural effusion, while the echocardiogram revealed the presence of a cardiac mass in the right atrium, mobile and attached to the interatrial septum (figure 1). Differential diagnosis was between thrombi and myxoma. Low-molecular-weight heparin was administered to the patient as a therapy for pulmonary embolism.

During her nursery, it was observed that she had steadily worsening thrombocytopenia and prolonged aPTT, so more thorough blood tests were done as far as coagulant disorders are concerned. Based on lupus anticoagulant (LA) positivity, anticardiolipin (aCL) antibodies and β_2 GPI remarkable elevated, the diagnosis of antiphos-

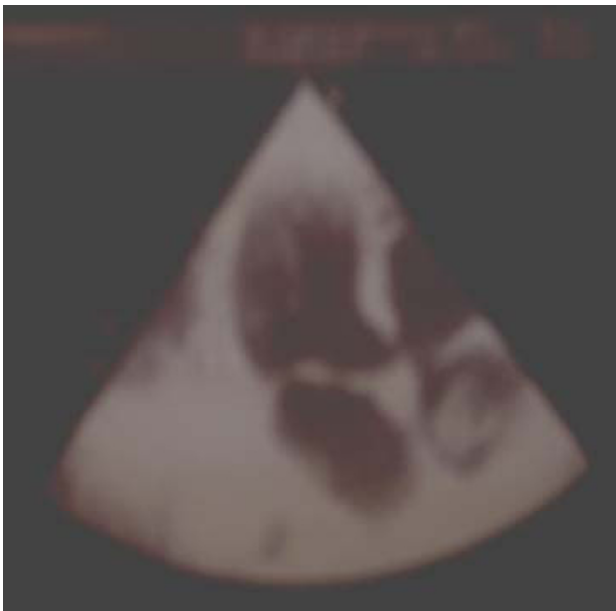

Figure 1
Echocardiography of a right atrial mass, 2 × 2 cm, attached to the atrial septum.

pholipid syndrome was suggested. Because patients with antiphospholipid syndrome often develop thrombi it was thought that the mass in the right atrium was a thrombi.

The patient underwent a magnetic resonance imaging, as a more helpful imaging technique for surgical planning in order to remove the thrombi. Not only the size and the location of the cardiac mass were better depicted, but also pulmonary emboli were revealed on both lower lobes, especially on the right one (figure 2).

The mass was successfully excised and the histological examination confirmed the macroscopic diagnosis of myxoma and not a thrombi. She had a good postoperative course and was discharged with oral anticoagulant therapy maintaining an international normalized ratio (INR) between 2,5 and 3. Follow-up echocardiograms showed no recurrence of the myxoma and repeated blood tests after 12 weeks confirmed the diagnosis of antiphospholipid syndrome.

Conclusion

Cardiac tumors, either primary or secondary, are uncommon, reported in 0,056% to 1,23% in autopsy series [1]. Primary cardiac tumors are accounting for 76%, in a multicentre retrospective analysis [2], with 75% of these to be benign and 50% of the last group to be myxomas. They occur mainly in women, between the third and sixth decades of life [3] and they may develop in any chamber of the heart. The majority is situated in the atria (75% in the left atrium), with only 5-10% presented in the ventricles [4]. Atypical locations and multiple myxomas occur in familiar cases [5].

Macroscopically, there are two types of myxomas: a solid and round shaped with a nonmobile surface and a polypoid one with an asymmetrical, soft and mobile surface [6]. It is thought that multipotential mesenchymal cells from embryonic rests give rise to myxomas [4]. Histologically, they consist of a mixoid matrix composed of an

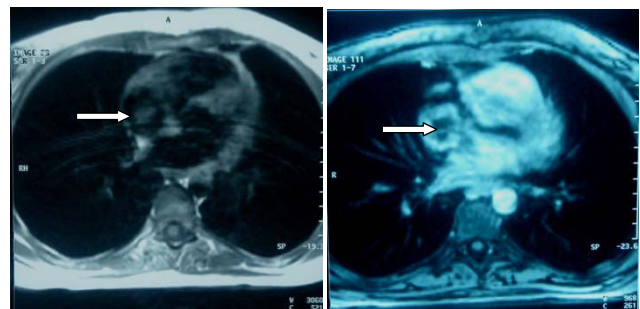


Figure 2
MRI showing a mass occupying the right atrium.

acid-mucopolysaccharide-rich stroma and polygonal cells with scant eosinophilic cytoplasm throughout it. They may, also, contain cysts, calcifications, areas of haemorrhage or extra-medullary haematopoiesis as well as gland-like elements [7].

The clinical features depend on the size, the location, the mobility and the fragility of the mass and they may be constitutional, obstructive or embolic. The constitutional symptoms, such as fever, weight loss, anemia, arthralgias and rash, rely on an immunologic response with an increase of CRP, IL-6 and γ -globulin [8] due to bleeding and degeneration within the mass and releasing tumor fragments. The laboratory tests may mimic those of autoimmune and rheumatic diseases [9] and this is usually the main reason for delaying the diagnosis of a myxoma [6]. In case of a right atrial myxoma, the obstruction of tricuspid valve can give rise to signs of right-sided heart failure, such as dyspnea, cyanosis, general edema or syncope [10]. Moreover, the blockage of the vena cava can result in a Budd-Chiari syndrome with acute abdominal pain [11]. The most important life-threatening complication is pulmonary embolism and it is demonstrated in 40% of patients with cardiac tumors. Rarely, it has been reported cases of infected right atrial myxomas [12].

As far as the diagnosis is concerned, transthoracic echocardiography is the method of choice for the detection and description of the size, shape, location, attachment to the cardiac wall and movement of the myxoma. Transesophageal echocardiography should be considered in case of clinical suspicion and nondiagnostic transthoracic echocardiography. Magnetic resonance imaging (MRI) is a quite expensive but more accurate technique in determining the structure and special tissue characteristics of the myxoma, *αποτελντας* an important role in surgical planning [13].

The differential diagnosis of a right atrial lesion includes both benign (myxoma, thrombus and vegetations) and malignant masses and the confirmation of the diagnosis is the histopathologic examination.

Therapeutic approach consists only of surgical excision of the mass as soon as possible, especially on its symptomatic forms of embolism and heart failure. A better pre-operative assessment can allow a minimally invasive approach with video-thoracoscopy [14]. The intra-operative mortality rate is low and the short and long-term prognosis excellent. Follow-up echocardiography is needed to rule out cases of recurrence.

The second clinical condition that was present in our case report was the antiphospholipid syndrome (APS) which

diagnosis was established six weeks after the surgical removal of the myxoma. This syndrome is a disorder characterized by recurrent venous or arterial thrombosis and/or fetal losses associated with characteristic laboratory abnormalities, such as persistently elevated levels of antibodies directed against membrane anionic phospholipids (anticardiolipin antibody, antiphosphatidylserine) or their associated plasma proteins, predominantly beta-2 glycoprotein I (β_2 GPI), or evidence of a circulating anticoagulant. It is presented either as primary or secondary to rheumatic or autoimmune disorders, mainly systemic lupus erythematosus (SLE) and has been documented a young female predominance.

The diagnostic criteria are clinical and laboratory ones. The clinical criteria are: 1) one or more confirmed vascular thrombotic episode, and 2) pregnancy morbidity. The laboratory criteria are: elevated levels of 1) aCL antibodies, 2) β_2 GPI, 3) LA, on at least 2 occasions at least 12 weeks apart. There should be at least one clinical and one laboratory criterion present for the diagnosis [15].

The medical management of the syndrome is anticoagulant therapy with oral vitamin K antagonists and INR between 2 and 3, so as to eliminate the thrombosis risk. In cases of high levels of antibodies but no symptoms, patients should be treated with low-dose aspirin [16].

Usually patients have only one disease that can explain their symptoms. In our case report the patient had two different clinical conditions that were responsible for her symptoms. We can only suggest what was responsible for her onset clinical symptoms that led to diagnostic laparotomy. Some authors have reported that the blockage of the vena cava by a myxoma, can result in a Budd-Chiari syndrome with acute abdominal pain. This scenario can provide a reasonable explanation but we were not able to prove it. The other question that rises reasonably is that if there was a connection between the myxoma and the presence of antiphospholipid syndrome. While reviewing the literature, only Quintanilla et al. has reported a similar case and suggested that that interleukin-6 produced by the myxoma could trigger an immunological reaction leading to the primary antiphospholipid syndrome [17]. We have to emphasize that there was no evidence of antiphospholipid syndrome relapse after the myxoma excision. On the other hand many cases of APS in the literature have reported cardiac thrombi mimicking myxoma [18]. In our case report if the myxoma was smaller it would result in a delay of diagnosis, because no surgery would be performed for the myxoma excision.

In conclusion, it should be mentioned that even though both right atrial myxoma and antiphospholipid syn-

drome are uncommon conditions, separately or not, there should be always clinical suspicion in order to prevent their serious and probably fatal complications.

Consent

Written informed consent was obtained from the patient for publication of this case report and any accompanying images. A copy of the written consent is available for review by the Editor-in-Chief of this journal.

Competing interests

The authors declare that they have no competing interests.

Authors' contributions

PC was the cardiologist that diagnosed the myxoma and participated in the drafting of the manuscript. SK, KS and PT have been involved in drafting the manuscript. MS and AE reviewed the literature and helped to draft the manuscript. NP has given final approval of the version to be published. All authors read and approved the final manuscript.

References

- Lam KY, Dickens P, Chan AC: **Tumors of the heart. A 20-year experience with a review of 12,485 consecutive autopsies.** *Arch Pathol Lab Med* 1993, **117**:1027-1031.
- Pilar Arnaiz G, Isabel Toledo G, Arturo Borzutzky S, Gonzalo Urcelay M, Felipe Heusser R, Francisco Garay G, Elisa Castillo N, Lida Toro R, Pedro Becker R, Claudio Arretz V, Samuel Córdova A: **Comportamiento clínico de los tumores cardiacos desde el feto hasta el adulto: un estudio multicentrico de 38 pacientes.** *Rev Med Chil* 2006, **134**:1135-1145.
- Reynen K: **Medical progress: cardiac myxomas.** *N Engl J Med* 1995, **333**:1610-1617.
- Wold LE, Lie JT: **Cardiac myxomas: a clinicopathologic profile.** *Am J Pathol* 1980, **101**:219-240.
- Carney JA, Hruska LS, Beauchamp GD, Gordon H: **Dominant inheritance of the complex myxomas, spotty pigmentation and endocrine overactivity.** *Mayo Clin Proc* 1986, **61**:165-172.
- Demir M, Akpınar O, Acartürk E: **Atrial myxoma: an unusual cause of myocardial infarction.** *Tex Heart Inst J* 2005, **32**:445-447.
- Heath D: **Pathology of cardiac tumors.** *Am J Cardiol* 1968, **21**:315-327.
- Endo A, Ohtahara A, Kinugawa T, Ogino K, Hisatome I, Shigemasa C: **Characteristics of cardiac myxoma with constitutional signs: multicenter study in Japan.** *Clin Cardiol* 2002, **25**:367-370.
- Hövels-Gürich HH, Seghaye MC, Amo-Takyi BK, Hügel W, Duchateau J, von Bernuth G: **Cardiac myxoma in a 6-year-old child-constitutional symptoms mimicking rheumatic disease and the role of interleukin-6.** *Acta Paediatr* 1999, **88**:786-788.
- Pucci A, Gagliardotto P, Zanini C, Pansini S, di Summa M, Mollo F: **Histopathologic and clinical characterization of cardiac myxoma: review of 53 cases from a single institution.** *Am Heart J* 2000, **140**:134-138.
- Bitner M, Jaszewski R, Wojtasik L, Zaslonka J: **Unusual course of right atrial myxoma, masked by acute abdominal pain, and complicated by pulmonary embolus.** *Scan Cardiovasc J* 1998, **32**:371-376.
- Prince JM, Larsen R, Janner D: **Infected cardiac myxoma.** *Pediatr Inf Dis J* 2002, **21**(2):177-178.
- Yuan SM, Shinfield A, Lavee J, Kuperstein R, Haizler R, Raanani E: **Imaging morphology of cardiac tumours.** *Cardiol J* 2009, **16**:25-35.
- Selkane C, Amahzoune B, Chavanis N, Raïsky O, Robin J, Ninet J, Obadia JF: **Changing management of cardiac myxoma based on a series of 40 cases with long-term follow-up.** *Ann Thorac Surg* 2003, **76**:1935-1938.
- Miyakis S, Lockshin MD, Atsumi T, Branch DW, Brey RL, Cervera R, Derksen RH, DE Groot PG, Koike T, Meroni PL, Reber G, Shoenfeld Y, Tincani A, Vlachoyiannopoulos PG, Krilis SA: **International consensus statement on an update of the classification criteria for definite antiphospholipid syndrome (APS).** *J Thromb Haemost* 2006, **4**:295-306.
- Lim W, Crowther MA, Eikelboom JW: **Management of the antiphospholipid antibody syndrome: a systematic review.** *JAMA* 2006, **295**(9):1050-1057.
- Quintanilla S, Ferrer S, Bravo M: **Myxoma and antiphospholipid antibody syndrome.** *Rev Med Chil* 1998, **126**(6):670-6.
- Gertner E, Leatherman JW: **Intracardiac mural thrombus mimicking atrial myxoma in the antiphospholipid syndrome.** *J Rheumatol* 1992, **19**(8):1293-8.

Publish with **BioMed Central** and every scientist can read your work free of charge

"BioMed Central will be the most significant development for disseminating the results of biomedical research in our lifetime."

Sir Paul Nurse, Cancer Research UK

Your research papers will be:

- available free of charge to the entire biomedical community
- peer reviewed and published immediately upon acceptance
- cited in PubMed and archived on PubMed Central
- yours — you keep the copyright

Submit your manuscript here:
http://www.biomedcentral.com/info/publishing_adv.asp

